

Stapled Haemorrhoidectomy When Performed with Concurrent Perianal Conditions*

Ng Kheng Hong *MBBS, MRCS*, Eu Kong Weng *MMed, FRCS*, Ooi Boon Swee *MBBS, FRCS*,
Heah Sieu Min *MB BCh, FRCS*, Tang Choong Leong *MMed, FRCS*, Francis Seow Choen *FRCS, FAMS*
Department of Colorectal Surgery, SGH

ABSTRACT

Background. Stapled haemorrhoidectomy is fast becoming the surgery of choice for the treatment of third and fourth degree prolapsed piles. However, the occurrence of concomitant perianal conditions with piles is not uncommon. So far, there is no report in the literature that looks into the use of stapled haemorrhoidectomy and concurrent perianal conditions.

Methods. A retrospective review of 1106 cases of stapled haemorrhoidectomy done between August 2000 to July 2002 was conducted.

Results. Over the 2-year period, we encountered 44 cases which had concurrent perianal conditions when stapled haemorrhoidectomy was performed. Fibroepithelial polyps that were found in 25 of these patients intra-operatively were excised before stapled haemorrhoidectomies were carried out. Six cases had symptomatic chronic anal fissure, and had lateral anal sphincterotomy performed in the same setting. Of the 7 patients who had asymptomatic fissure, 1 became symptomatic 4 months later and had lateral anal sphincterotomy done. Three patients had fistula-in-ano and had fistulectomy done concurrently. One of these patients developed an abscess later. Two patients had proctitis while 1 had an anal ulcer. None of these 44 patients had major complications of stapled haemorrhoidectomy.

Conclusion. Stapled haemorrhoidectomy can be performed safely in the presence of concurrent perianal conditions, except in the presence of significant anorectal abscess,

Keywords: anal fissure, fistula-in-ano, perianal conditions, stapled haemorrhoidectomy

INTRODUCTION

Stapled haemorrhoidectomy is fast becoming the surgery of choice for the treatment of third and fourth degree prolapsed piles. However, the occurrence of concomitant perianal conditions with piles is not uncommon. So far, there is no report in the literature that looks into the use of stapled haemorrhoidectomy and concurrent perianal conditions.

METHODS

We did a retrospective review of 1106 cases of stapled haemorrhoidectomy done over a period of about 2

years from August 2000 to June 2002 in the Department of Colorectal Surgery, Singapore General Hospital. There were about 44 cases with concurrent perianal conditions like fibroepithelial polyps, anal fissure, fistula-in-ano, rectal ulcer and proctitis. After discharge from the hospital, all patients were followed up in the outpatient clinic about 2 to 4 and 8 to 12 weeks later. The patients were reviewed clinically with regard to linear analogue pain score, satisfaction and faecal continence. At the time of the study, telephone interviews were conducted for all the patients to reassess pain, faecal continence and overall satisfaction with the surgery. Clinical outcomes analysed included post-operative pain, anal continence, complications, readmission, re-operation, duration of follow-up and overall satisfaction.

*Presented at 14th SGH Annual Scientific Meeting held on 26 to 27 September 2003.

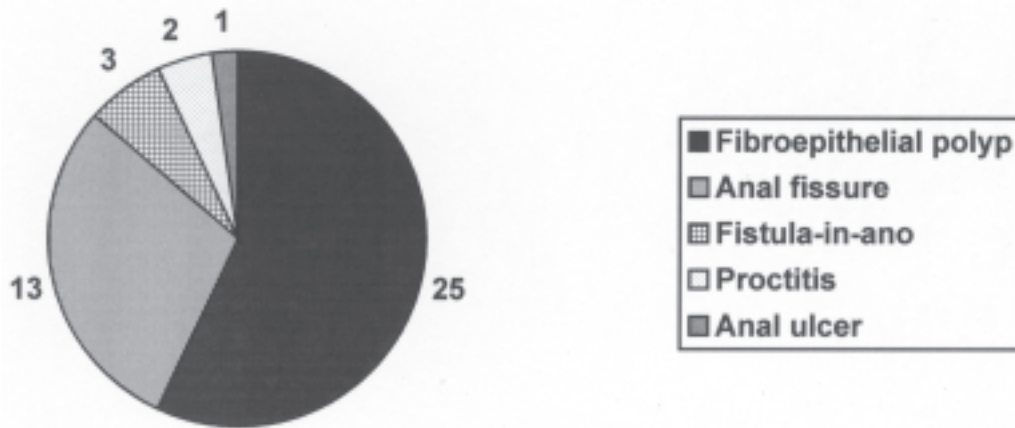


Fig. 1. Frequency of various concurrent perianal conditions.

Stapled haemorrhoidectomy was performed using a modification of the Longo technique, with PPH01® Stapler (Ethicon Endosurgery, Cincinnati, OH).¹ Lubricated Circular Anal Dilator (CAD33®; Ethicon Endosurgery) was first introduced into the anal canal, resulting in a reduction of the prolapsed third and fourth degree pile and the associated skin tags. The Purse String Anoscope® (Ethicon Endosurgery) was then inserted through the CAD33®, and a circumferential pursestring of 2-0 polypropylene was placed 2 to 3 cm proximal the dentate line. The Hemorrhoidal Circular Stapler (HCS33®; Ethicon Endosurgery) was then inserted through the pursestring after it had been maximally opened. The pursestring was then tied around the anvil shaft. The threads of the pursestring were pulled through the left lateral hole of the HCS33® and pulled down as the gun was spontaneously tightened and introduced into the anal canal. In the female patient, the vagina was examined to exclude its inclusion. Once the stapler is fully tightened, it is fired. Haemostasis along the stapler line was then ensured using diathermy and Vircyl 3-0 suture.

For patients with symptomatic chronic anal fissures and piles, open lateral internal sphincterotomy was performed before stapled haemorrhoidectomy. This was done using a short vertical incision in the lateral anal canal (mostly on the left of the patient at the 3 o'clock position). The lower fibres of internal anal sphincter were then isolated using an artery forcep and then incised. The small wound was then left open.

For the 3 patients with low fistula-in-ano, the tracts were identified using small malleable probe and laid open using diathermy. The tracts were then curettaged and tissue sent for histology. For the 25 patients with fibroepithelial polyps, the lesions were excised using

diathermy before stapled haemorrhoidectomy was performed.

RESULTS

Forty-four out of the 1106 cases of stapled haemorrhoidectomy performed had associated perianal conditions (Fig. 1). This accounted for 4.0% of the operations done. The median age of patients at presentation was 43 years (range: 26–55). There were 26 males and 18 females. The indications for surgery were bleeding in 86.3% and third degree prolapse in 68.2%.

Symptomatic Anal Fissure

Out of the 13 cases of chronic anal fissures, six were symptomatic and had severe pain after defecation. The median pain score for these 6 patients was 7.5 (range: 4–10) before surgery. These patients had lateral anal sphincterotomy done together with stapled haemorrhoidectomy. The median pain score was 6 (range: 5–10) on the same day after surgery, 1 (range: 0–4) at the time of follow-up 2 to 4 weeks later and 0.5 (range: 0–1) at median of 12 months after surgery (range: 5–18). Only 1 patient had post-operative bleeding, which responded to conservative treatment. One other patient had mild incontinence at 3 weeks which resolved subsequently. The median satisfaction score was 8 (range: 7–10).

Asymptomatic Anal Fissure

Seven patients had asymptomatic chronic anal fissures. No sphincterotomy was performed when stapled haemorrhoidectomy was undertaken. The pain experienced by these patients was lower than in those who had lateral anal sphincterotomy undertaken concurrently. None of the patients had complications,

Table 1. Pain scores and satisfaction scores after stapled haemorrhoidectomy performed with concurrent perianal conditions. Values are median (range).

Concurrent Perianal Conditions	Pain Before Surgery*	Pain Immediately After Operation*	Pain at 2–4 weeks*	Overall Satisfaction*
Symptomatic anal fissure	7.5 (4–10)	6 (5–10)	0.5 (0–1)	8 (7–10)
Asymptomatic anal fissure	0	3 (2–10)	1 (0–3)	8.5 (8–10)
Fistula-in-ano	0	4.5 (2–7)	1.5 (0–3)	7.5 (7–8)
Proctitis/anal ulcer	0	5.5 (5–6)	0.5 (0–1)	10 (7–10)
Fibroepithelial polyps	0	4 (1–6)	0	9 (7–10)

*median (range)

readmission or re-operation. One of these 6 patients became symptomatic 4 months later with severe pain during defecation. Lateral anal sphincterotomy was later performed and the patient was pain free when reviewed 10 months later.

Fistula-In-Ano

For the 3 patients with fistula-in-ano, 2 had simple low anal fistulas that were laid open. Stapled haemorrhoidectomy was performed with the anastomosis proximal to the internal opening of the fistula. Post-operatively, 1 patient had post-operative bleeding from the stapler line, which resolved with submucosa adrenaline injection. The other patient was readmitted 5 days after discharge from hospital for persistent perianal pain. This patient was treated symptomatically with simple oral analgesia and was discharged the following day. The third patient had atypical horse-shoe type of fistula-in-ano, with external opening at the 3 and 9 o'clock positions and internal opening at the 12 o'clock position. These tracts were laid open. However, the patient continued to have pain and fever post-operatively. This was attributed to a collection of pus at the base of the scrotum. Re-operation was done to drain the abscess.

Anorectal Inflammation

Two patients had evidence of non-specific proctitis at the time of stapled haemorrhoidectomy. Biopsies of the rectal mucosa were taken. None of them developed complications after surgery. One patient had mild inflammatory anal ulcer and did not develop complications as well.

On the whole, 5 out of 44 patients (11.3%) developed minor complications of bleeding, pain and localised abscess in the immediate post-operative period. None of these 44 patients developed major complications related to stapled haemorrhoidectomy like persistent pain, rectovaginal fistula, anastomotic breakdown,

recurrence of prolapse, anal incontinence and anal canal stenosis. The median pain score was 6 (range: 2–10) on the same day after surgery and 1 (range: 0–4) at 2 to 4 weeks after surgery. The median overall satisfaction was 9 (range: 7–10). Table 1 summarises the pain experienced and satisfaction scores of patients in this study. All patients were fully continent at 8 to 12 weeks following surgery.

DISCUSSION

Stapled haemorrhoidectomy was first described by Longo *et al* in 1999.² Now, it is fast becoming the procedure of choice for the treatment of third and fourth degree haemorrhoids.^{3–15} The use of circular stapler results in a reduction of vascular supply to the haemorrhoids, excision of redundant rectal mucosa, reduction and fixation of prolapse haemorrhoidal tissue and preservation of anal transitional zone. The main advantage of this technique is the reduction in post-operative pain. In fact, it has been shown in several series that it is associated with less post-operative pain, shorter hospital stay and faster recovery. This operation can also be performed in the day surgery setting with minimal inconvenience to the patients, like conventional haemorrhoidectomy.¹⁶

Complications related to the use of stapled haemorrhoidectomy have been reported. These complications can be minor like bleeding from anastomosis, perianal pruritis and pain. Major complications include incontinence, persistent pain, rectovaginal fistula, gross anastomotic breakdown and formation of pelvic abscess.^{17–19}

However, the presences of haemorrhoids with other perianal conditions are not uncommon. Conventional haemorrhoidectomy can usually be performed safely when these conditions are present. However, it is not known whether stapled haemorrhoidectomy can be performed safely with perianal conditions like fibroepithelial polyps, chronic anal fissure, fistula-in-ano and inflammation of the anorectal region.

With regard to chronic anal fissure, manual dilatation was commonly performed in the past. The use of a dilator in stapled haemorrhoidectomy has the same effect in the treatment of chronic anal fissure. For 6 of our patients with asymptomatic chronic anal fissure, stapled haemorrhoidectomy was sufficient. One of these patients became symptomatic after 3 months and was treated with lateral internal anal sphincterotomy. For patients who were symptomatic, lateral internal anal sphincterotomy was performed in the same setting.¹⁹ Though there was risk of internal sphincter injury during stapled haemorrhoidectomy causing possible anal incontinence, the addition of internal anal sphincterotomy did not appear to have increased this complication.²⁰ All 6 patients treated were well at mean of 3 months follow-up, with only 1 patient having transient anal incontinence that resolved at 3 months post-operation.

Mild inflammation of the anorectal region does not appear to affect the outcome of stapled haemorrhoidectomy. With stapled anastomosis of the intestines, there is always a concern that inflamed tissue is more prone to dehiscence and subsequent breakdown. However, in 3 of our patients, there was no complication with regard to the anastomosis in stapled haemorrhoidectomy.

The presence of low fistula-in-ano is not a contraindication to the use of stapled haemorrhoidectomy. However, when there is high or complex fistula-in-ano and presence of associated abscess, the treatment of these problems should take precedence while the problem of haemorrhoids could be addressed later. Stapled haemorrhoidectomy can be performed in the presence of fibroepithelial polyps but the excision of these polyps may result in an increase in the immediate post-operative pain.

In our small series of patients, there was 1 patient with bleeding from the anastomosis, 1 with significant pain while another had transient incontinence. There were no complications related to permanent incontinence, persistent pain, anastomotic breakdown or formation of abscess. In fact, the patients' duration of stay in the hospital was relatively short.

CONCLUSION

In our limited experience, stapled haemorrhoidectomy can be performed in the presence of concurrent perianal conditions with minimal complications. However, the severity of post-operative pain may be greater. In the presence of anorectal sepsis, the use of stapled haemorrhoidectomy should be delayed.

REFERENCES

- Lloyd D, Ho KS, Seow-Choen F. Modified Longo's hemorrhoidectomy. *Dis Colon Rectum* 2002; 45:416-7.
- Longo A. Treatment of hemorrhoidal disease by reduction of mucosa and hemorrhoidal prolapse with a circular suturing device: a new procedure. *Proceedings of the 6th World Congress of Endoscopic Surgery*. Bologna: Mundozzi Editore 1998;777-84.
- Seow-Choen F. Stapled haemorrhoidectomy: pain or gain. *Br J Surg* 2001; 88:1-3.
- Ho YH, Seow-Choen F, Tsang C, Eu KW. Randomized trial assessing anal sphincter injuries after stapled haemorrhoidectomy. *Br J Surg* 2001; 88:1449-55.
- Mehigan BJ, Monson JR, Hartley JE. Stapling procedure for haemorrhoids versus Milligan-Morgan haemorrhoidectomy: randomised controlled trial. *Lancet* 2000; 355:782-5.
- Rowell M, Bello M, Hemingway DM. Circumferential mucosectomy (stapled haemorrhoidectomy) versus conventional haemorrhoidectomy: randomised controlled trial. *Lancet* 2000; 355:779-81.
- Ortiz H, Marzo J, Armendariz P. Randomized clinical trial of stapled haemorrhoidectomy versus conventional diathermy haemorrhoidectomy. *Br J Surg* 2002; 89:1376-81.
- O'Bichere A, Khalil KH, Sellu DP. Closed haemorrhoidectomy: a randomized trial of sutured versus stapled methods. *Br J Surg* 2000; 87:1352-5.
- Peng BC, Jayne DG, Ho YH. Randomized trial of rubber band ligation vs. stapled hemorrhoidectomy for prolapsed piles. *Dis Colon Rectum* 2003; 46:291-7.
- Jayne DG, Seow-Choen F. Modified stapled haemorrhoidectomy for the treatment of massive circumferentially prolapsing piles. *Tech Coloproctol* 2002; 6:191-3.
- Hetzer FH, Demartines N, Handschin AE, Clavien PA. Stapled vs excision hemorrhoidectomy: long-term results of a prospective randomized trial. *Arch Surg* 2002; 137:337-40.
- Ooi BS, Ho YH, Tang CL, Eu KW, Seow-Choen F. Results of stapling and conventional hemorrhoidectomy. *Tech Coloproctol* 2002; 6:59-60.
- Shalaby R, Desoky A. Randomized clinical trial of stapled versus Milligan-Morgan haemorrhoidectomy. *Br J Surg* 2001; 88:1049-53.
- Ganio E, Altomare DF, Gabrielli F, Milito G, Canuti S. Prospective randomized multicentre trial comparing stapled with open haemorrhoidectomy. *Br J Surg* 2001; 88:669-74.
- Jayne DG, Seow-Choen F. Modified stapled haemorrhoidectomy for the treatment of massive circumferentially prolapsing piles. *Tech Coloproctol* 2002; 6:191-3.
- Guy RJ, Ng CE, Eu KW. Stapled anoplasty for haemorrhoids. A comparison of ambulatory vs in-patient procedures. *Colorectal Dis* 2003; 5:29-32.
- Cheetham MJ, Mortensen NJ, Nystrom PO, Kamm MA, Phillips RK. Persistent pain and faecal urgency after stapled haemorrhoidectomy. *Lancet* 2000; 356:730-3.
- Molloy RG, Kingsmore D. Life threatening pelvic sepsis after stapled haemorrhoidectomy. *Lancet* 2000; 355:810.
- Maw A, Eu KW, Seow-Choen F. Retroperitoneal sepsis complicating stapled hemorrhoidectomy: report of a case and review of the literature. *Dis Colon Rectum* 2002; 45:826-8.
- Nyam DC, Pemberton JH. Long-term results of lateral internal sphincterotomy for chronic anal fissure with particular reference to incidence of fecal incontinence. *Dis Colon Rectum* 1999; 42:1306-10.